



Department Of Orthopaedics & Traumatology Queen Mary Hospital University Of Hong Kong Medical Centre Newsletter



Vol. 4, Issue 2, September 2004

Arthroscopic treatment of synovial pathology

Dr Lee Kin-man

Arthroscopy was developed as an offshoot of cystoscopy and was first used to look inside the knee joint in 1912. With continuous advance in technology, its application was widely extended to treat different pathologies in different joints.

In general, arthroscopic surgery has the advantage of being less invasive and so resulted in less post-operative pain, shorter rehabilitation time and faster recovery. The surgical wounds are small and more cosmetically acceptable. Many patients have their surgery on outpatient basis. However, specialized instruments and specially trained surgeons are required to perform arthroscopic procedures. Major complications generally occur in less than 1 percent in experienced hands.

Apart from treating many sport injuries, arthroscopy is widely used in treating synovial pathologies nowadays.

Inflammatory joint disease

Various kinds of inflammatory joint diseases including rheumatoid arthritis and seronegative arthritis can be treated with arthroscopic synovectomy at some stage. Synovectomy is particularly successful in treating arthritis with only one or two joints involvement and in the early stage with less significant joint erosion. In rheumatoid elbow for example, arthroscopic synovectomy has been done as a less invasive alternative to open surgery because of faster post-operative rehabilitation and versatile access to the elbow joint. The same apply to other joints like the knee and

shoulder. Studies showed that arthroscopic synovectomy for rheumatoid elbow can reliably alleviate pain, but only patients with mild radiographic changes had favorable results with regard to total function in long term. However, extensive joint involvement is not an absolute contra-indication because even in patients with advanced disease, synovectomy may result in acceptable pain relief and sometimes even increased range of motion. (Fig. 1, 2, 3 & 4)

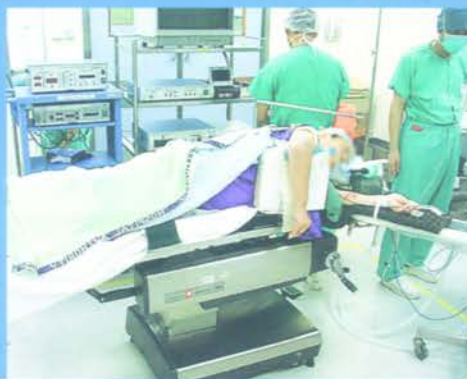

Fig.1 One possible positioning for patient going for elbow synovectomy.

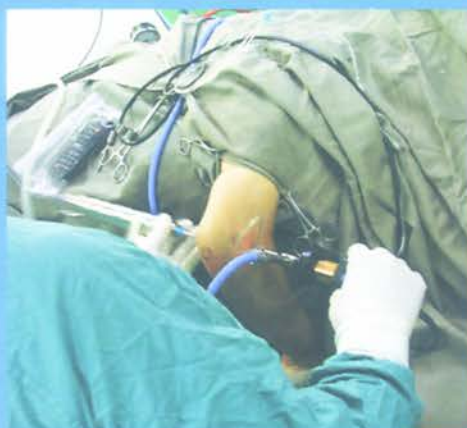

Fig.2 Surgeon performing right elbow arthroscopic synovectomy in a RA patient.

Editorial Board

Dr Jimmy Wong (Chief Editor)
Senior Medical Officer

Dr Kenneth Cheung
Associate Professor

Ms Teresa Li
Department Operations Manager

Dr TL Poon
Consultant

C/o Department of Orthopaedics & Traumatology

5/F Professors Block, Queen Mary Hospital,
Pokfulam, Hong Kong.

Tel : (852) 2855 4654

Fax : (852) 2817 4392

Email : ortho1@hkucc.hku.hk

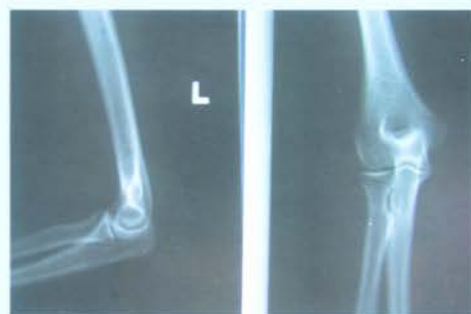

Fig.3 X-Ray of early RA elbow. Synovectomy has favourable long term result.

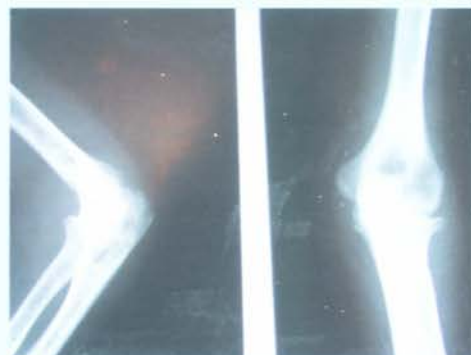

Fig.4 X-Ray of more advanced RA elbow. Synovectomy may result in pain relief.

Haemophilic synovitis

Haemorrhagic synovitis occurs due to repeated haemarthrosis in haemophilic patients. Arthroscopic synovectomy can provide pain relief and reduce the incidence of haemarthrosis in early stage of haemophilic arthropathy (Fig. 5).

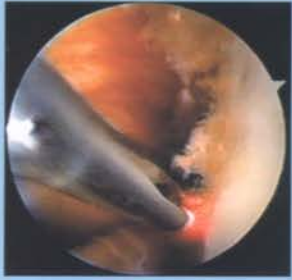

Fig.5 Laser treatment in haemorrhagic synovitis.

Bursitis

Inflammation of bursa can occur due to mechanical irritation directly in the region of bony prominence or it can arise spontaneously. Common sites are over olecranon and patella. Arthroscopic bursectomy can be performed with mild post-operative pain and minimal surgical scar. (Fig. 6, 7 & 8)

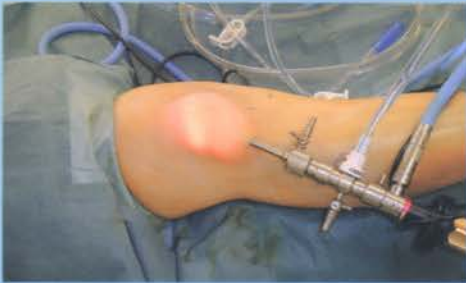

Fig.6 Arthroscopy in right pre-patellar bursa, preparing for bursectomy.

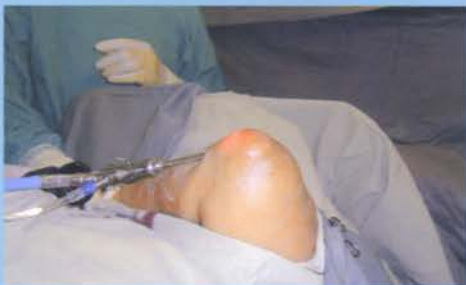

Fig.7 Arthroscopy in left olecranon bursa, preparing for bursectomy.

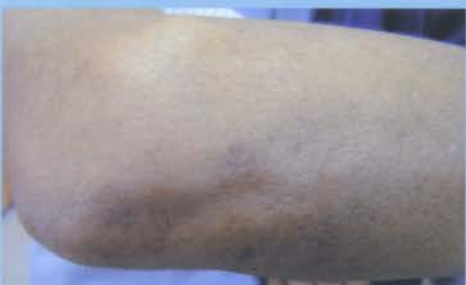

Fig.8 Minimal scars left after arthroscopic olecranon bursectomy.

Synovial tumor-like pathology

There are several tumor-like conditions of synovium that can be treated successfully with arthroscopic excision or synovectomy. These included pigmented villonodular synovitis (PVNS), lipoma arborescens and synovial osteochondromatosis.

PVNS is a primary disease of synovium characterized by exuberant proliferation with formation of villi and nodules. It presents with single joint pain, effusion, and swelling with thickened synovium. X-ray shows justacortical erosion. Arthroscopy shows brownish discoloured synovium with large, flattened nodules and villous proliferation. (Fig. 9)

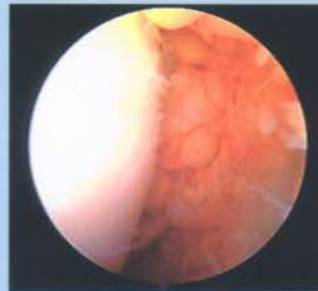
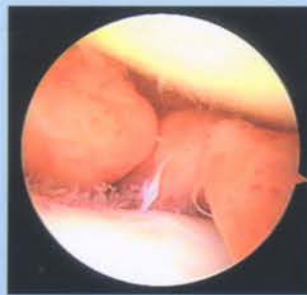
Fig.9 Arthroscopic views of PVNS.

Lipoma arborescens is a rare intra-articular lesion characterized by villous proliferation of synovium and hyperplasia of subsynovial fat. MRI shows characteristic T1-weighted hyperintense fat signals within the synovial proliferations. (Fig. 10 & 11)

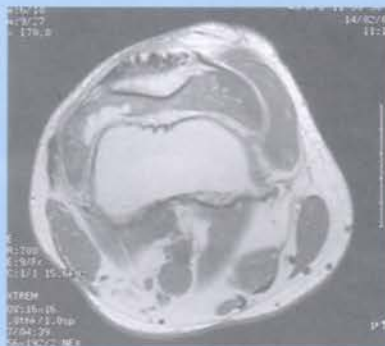


Fig.10 Characteristic MRI of lipoma arborescens in a knee (axial cut image showing the pathologic synovial proliferation between the patella & femur).

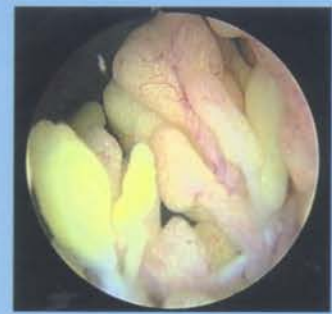


Fig.11 Arthroscopic view of lipoma arborescens.

Synovial osteochondromatosis is intrasynovial proliferation of lobules of cartilage with occasional ossified areas occurs within layers of the membrane. X-ray may show multiple loose bodies. Treatment consists of removal of loose bodies and synovectomy (Fig. 12 & 13)

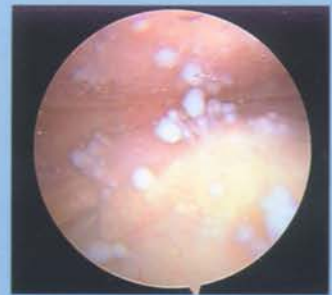

Fig.12 Arthroscopic view of synovium in synovial osteochondromatosis.

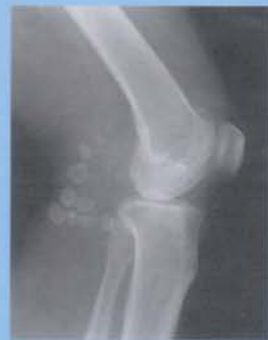

Fig.13 X-Ray showing multiple ossified loose bodies in synovial osteochondromatosis of knee.

Perspective

Arthroscopy was used in the treatment of a wide range of intra-articular conditions. Synovial pathology is only part of it. With better instruments & growing number of arthroscopists, more arthroscopic procedures are being performed. Its application had been extended from the early stage in the knee to nowadays in shoulder, elbow, ankle, hip, wrist, and even spine. New technology including laser, radiofrequency and electrothermal surgeries are being developed continuously. The demand for minimally invasive procedures is growing. Arthroscopy, being recognized as one of the most significant advances in orthopaedic in the past century, will continue to evolve and revolutionize orthopaedic surgery.

The Aging Skeleton – Orthopaedic perspective in the 21st century’ The First Hong Kong International Orthopaedic Forum

Dr Frankie Leung

The aging population is increasing in Hong Kong and it will create great challenges for the specialty of orthopaedics. Aging has significant effect on musculo-skeletal function. Age-related bone loss predisposes elderly individuals to the risk of osteoporotic fractures. Degeneration of articular cartilage frequently leads to the development of osteoarthritis. Degeneration of the intervertebral discs and facet joints contribute to spondylosis and spinal stenosis.

The Department of Orthopaedics and Traumatology has deliberated on the needs of health care professionals of all disciplines in managing this emerging health problem. The First Hong Kong International Orthopaedic Forum took place on 24-25 April, 2004 in the Faculty of Medicine Building and an impressive panel of faculty members, both local and international, in different disciplines of medicine was invited to showcase their work. Interesting cases were presented and discussed on a multidisciplinary level.

The first ever Orthopaedic Forum was a resounding success with more than 400 participants. It was hoped to raise the attention of all health care workers towards musculoskeletal problems of the elderly and the Forum will just serve as an initiation for further conjoint effort.



International Congress on Spinal Cord Regeneration and Rehabilitation

Dr HY Kwok

The Neuroscience Research Centre, MacLehose Medical Rehabilitation Centre and the Department of Orthopaedics and Traumatology, jointly organized a Conference “International Congress on Spinal Cord Regeneration and Rehabilitation”, on 17-18 April 2004 at the Faculty of Medicine Building, HKU. Over 150 delegates attended the conference. The international renowned speakers including Dr. Rainer Abel (Germany), Prof. Hong-yun Huang (China), Dr. Vernon W.H. Lin (USA), Dr. Yoichi Shimada (Japan), Prof. John Steeves (Canada), Prof. Chuan-Guo Xiao (China) and Prof. Xiao-Ming Xu (USA) made the conference interesting and stimulating for



discussion among the participants. The response from the participants was overwhelming, as the conference is one of the very first of its kind organized on a very specific topic “spinal cord regeneration and rehabilitation”.

The International Congress on Spinal Cord Regeneration and Rehabilitation Conference was attended by over 150 participants

Donations

Donor	Amount	Purpose
Mr. Lau Wah of Fong Shing (H.K.) Investment Co Ltd	HK\$300,000	Expenses incurred in the organization of the International Congress on Spinal Cord Regeneration and Rehabilitation in April 2004 and research activities to spinal cord regeneration and rehabilitation
Dr. Stanley Ho	HK\$3,000,000	Earmarked for the development of “Stem Cell and Tissue Engineering Laboratory”
Hantak Ortho-Technology Limited	HK\$168,000	To conduct biomaterials research
Mr. Hui Hoy	HK\$1,000,000	For department research
Stryker China Ltd	HK\$22,500	To support total joint reconstruction training and education for Mainland China surgeons
Mr. Ma Tin Tak	HK\$30,000	For department research and development purpose
Dr. David Fang	HK\$20,000	For education and research purposes
Dr. Duosai Lu	HK\$10,000	To support research works

Research Grants

Grants	Amount	Project Title	Investigators
Hong Kong Research Grants Council	HK\$939,968	The impact of the COL9A2-Q326W allele on intervertebral disc structure and degeneration	KMC Cheung, KSE Cheah, D Chan, WW Lu and KDK Luk
Hong Kong Research Grants Council	HK\$939,968	Novel prosthetic replacements for metacarpophalangeal (MCP) joints	SP Chow, I Gibson, AHW Ngan, KY Chiu, WP Ip, WW Lu
S.K. Yee Medical Foundation	HK\$496,760	Provision of individualized biomechanical and electrophysiological service for occupational low back disorder patients	KDK Luk, Y Hu, WW Lu

Area of Excellence (AoE) in Developmental Genomics and Skeletal Research

Dr Kenneth Cheung

Our Department played a leading role in securing a HK\$50 million grant from the University Grants Committee (UGC) to undertake research in bone and cartilage biology.

The Area of Excellence programme came about following a comprehensive review of higher education of Hong Kong by the University Grants Committee (UGC). The UGC advised the Government that Hong Kong would need world-class institutions with distinct areas of excellence in order to retain its leading economic position in the development of China and the Pacific Rim. These areas of excellence should build upon existing strengths and would be recognised internationally as of equal status to their peers in the same subject area, and justify the additional investment in state-of-the-art facilities and activities which would maintain them amongst the world leaders.

Prof John Leong (our previous Dept Head and current President of the Open University of Hong Kong), Prof Keith Luk and Dr. Kenneth Cheung from our department, together with scientists from the University of Hong Kong (Cheah KSE, Chan D, Chu I, Huang JD, Kung HF, Jin DY, Sham MH, Sham P, Shum DKY, Smith D, Song YQ, Yao KM, Zhou ZJ), University of Science and Technology (Chang D, Chow K, Zhang MJ), and Polytechnic University (Yip SP), made up the AoE team (Fig 1). Their AoE on "Developmental Genomics and Skeletal Research" were chosen amongst 41 initial proposals from the 8 UGC funded institutions. Key elements of the success included cooperation between scientists and clinicians from different institutions with diverse and complementary expertise, and support from the world class facilities of the HKU Genome Research Centre.

Announcing the award on 26th January 2004, Professor Sir Colin Lucas, Chairman of the UGC-AoE Sub Committee added, "The AoE Scheme is a very competitive and highly selective funding exercise and the Sub-Committee has applied very stringent standards in the evaluation of proposals. The two selected have clearly demonstrated a strong prospect for attaining international excellence and are areas which the UGC believes will help Hong Kong advance and compete internationally in the relevant fields." A total of HK\$95 million was awarded this year to 2 proposals, the other supported proposal was for HK\$45 million to the "Centre for Marine Environmental Research and Innovative Technology" from CityU/HKU/HKUST/CUHK/HKBU / PolyU.

The HK\$50 million awarded to our proposal will provide funding to acquire equipment, facilities, and personnel to support projects in helping to understand the regulation of bone and cartilage growth, how such growth and maintenance contribute to disease, and what genetic factors predispose to degenerative skeletal disorders. The team will employ a variety of state-of-the-art technologies in genomics, proteomics, cell biology and animal models to identify the genes, proteins and regulatory networks that are responsible for the health and disease of the skeleton.

Prof. John Leong, who helped shape the programme and continues his involvement in the AoE as a collaborator, commented "this prestigious award highlights the importance of understanding musculo-skeletal disorders."

The AoE funding will initially be for 5 years. At the end of which, the team would have gained significant understanding of the basic molecular

mechanisms of bone and cartilage formation, maintenance and disease. One example would be the genetic predisposition and mechanisms of intervertebral disc degeneration (Fig 2). Through this understanding, innovative treatment strategies to treat musculoskeletal disorders can be identified. This may include treatment by gene therapy, cell therapy and tissue engineering. This would benefit individuals suffering from many musculoskeletal disorders, and put Hong Kong at the forefront of skeletal research worldwide.

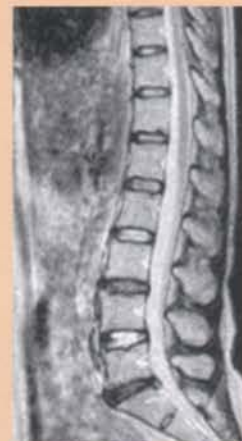

Fig. 2: Lumbar MRI from an individual with genetic predisposition

For more information:

UGC Press Release on Result for the Third Round AoE:

<http://www.ugc.edu.hk/english/documents/press/pr260104e.html>

Area of Excellence (AoE) Scheme:

<http://www.ugc.edu.hk/english/aoe.html>

AoE on Developmental Genomics and Skeletal Research:

<http://www.hku.hk/biochem/>

Call for volunteers

As part of this programme we are trying to identify genetic factors that predispose individuals to intervertebral disc degeneration. We need volunteers between the ages of 18 and 50 who are willing to undertake an MRI examination of the lumbar spine and provide a blood sample for DNA analyses. In return they will be given a free examination of their back. Interested individuals please contact Ms Yu by fax [28174392] or e-mail [yupei@hkucc.hku.hk], providing your name and contact details.



Fig. 1: Members of the AoE team.

Correspondence: Editorial Board, Newsletter,

Department of Orthopaedics & Traumatology, 5/F Professorial Block, Queen Mary Hospital, Pokfulam, Hong Kong.

Tel: (852) 2855 4654

Fax: (852) 2817 4392

Email: ortho1@hkucc.hku.hk